

# Mineralization Effect of Homeopathic Substances on Turkeys Bones

Sergio Canello<sup>1</sup>

Paolo Bissaro<sup>2</sup>

Mara Granata<sup>3</sup>

Alessandro Di Cerbo<sup>4\*</sup>

Luciano De Angelis<sup>5</sup>

<sup>1</sup>*Sanypet, Bagnoli di Sopra, Padova, Italy; Tel. +390429785401, mail. Sergio.sanypet@forza10.com*

<sup>2</sup>*Freelancer DVM, Padova, Italy; tel. +393485103600, mail. paolo.bissaro@pec.pd.fnovi.it*

<sup>3</sup>*Freelancer DVM, Novara, Italy; tel. +39032173608, mail. mara.granata@pec.no.fnovi.it*

<sup>4</sup>*School of Specialization in Clinical Biochemistry, "G. d'Annunzio" University, Chieti, Italy; Tel. +393923731318, mail. alessandro811@hotmail.it*

<sup>5</sup>*Freelancer DVM, Roma, Italy; mail. luciano.deangelis@pec.rm.i*

\* (Corresponding author)

**KEY WORDS:** bone mineral density, homeopathic substances, computerized axial tomography

## ABSTRACT

**Objectives:** This study was conducted to evaluate the bone tropism of homeopathic substances, appropriately diluted and dynamized, in turkeys.

**Materials and Methods:** Forty male turkeys were randomly divided into two groups, 20 each, and were fed either a homeopathic mixture (treated) or a placebo (control) throughout the duration of the growing cycle (almost 5 months). At the beginning and end of the cycle, 13 subjects

from the first group and 7 in the second were randomly evaluated and a computerized axial tomography was performed in order to measure bone mineral density of the sternum, femur, and humerus .

**Results:** A significant increase in bone mineral density of treated subject, which were more sthenic and vital, was observed with respect to the controls at the end of treatment (\*\*P < 0.01). Moreover, a decreased number of animals discarded during the cycle was also observed in treated group with respect to control.

**Conclusions:** The present study, which has to be considered as preliminary, is one of the

first to demonstrate scientific evidence of the effectiveness of substances diluted and potentized beyond the Avogadro constant. However, considering the randomized system of choice and the homogeneity of the achieved results, a future work addressed in humans would be advisable.

## INTRODUCTION

Literature reports have shown that some substances of vegetable and mineral origin (*Calcarea carbonica*,<sup>1</sup> *Symphytum officinalis*,<sup>2</sup> and *Equisetum arvensis*<sup>3</sup>) individually diluted and dynamized according to homeopathic methodology possess a bone tissue tropism.

The substance named *Symphytum officinalis* derives from the Boraginaceae family, which has been empirically used in the past in fractures, wounds, and treatment of bruises<sup>4</sup> due to its ability to enhance the healing process.<sup>5</sup> Moreover, its homeopathic use has been proven successful in bone related pathologies such as osteoporosis, osteogenesis imperfecta, and rickets.<sup>6,7</sup> In the veterinary practice, it has been used to treat cats affected by hyperparathyroidism and to the arrest the evolution of the clinical picture of osteoporosis, which is characterized by the progressive weakening of the cortex of the long bones and the appearance of spontaneous fractures.<sup>8</sup> On the other hand a rapid remineralization of bone tissue has been observed in more sensitive subjects.

Even *Calcarea carbonica* (calcium carbonate), individually or in association with *Calcarea fluorica* and *phosphorica* (fluoride and calcium phosphate) known as Tricalcarea, has a bone tissue tropism at homeopathic dilutions.<sup>9</sup> Moreover, its use improves clinical pictures caused by defects of absorption and mobilization of calcium.<sup>10,11</sup>

As to *Equisetum arvensis*, belonging to Equisetaceae family is an effective mineralizing agent, especially on young animals suffering from rickets.<sup>12</sup>

The use of these substances at homeopathic concentrations with animals can have a double benefit: improve the resistance to

pathogenic noxae (Mycoplasmosis (*Mycoplasma gallisepticum*)), rhinotracheitis, difteritis, chlamydiosis, aspergillosis, viral arthritis, coccidiosis (*Eimeria* spp), and intestinal parasitosis, and determine a qualitative improvement of the products of animal origin intended for human consumption.

In this preliminary work, we investigated the effect and influence of a homeopathic mixture of *Calcarea carbonica*, *Symphytum officinalis*, and *Equisetum arvensis* on musculoskeletal development and calcium hydroxyapatite concentration of vertebral spongiosis as well as the resistance of farmed turkeys to disease development. We chose farmed turkeys due to their exasperated growth boost, which usually causes the onset of serious diseases of the skeletal system with the consequent high percentage of discarded animals during the growing cycle.

## MATERIALS AND METHODS

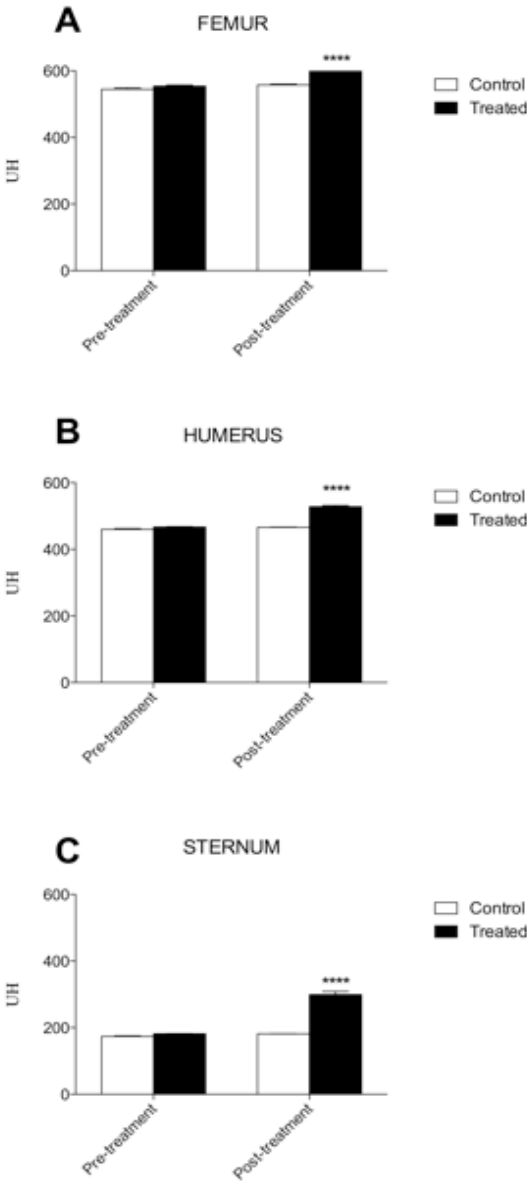
Forty male farmed turkeys (BIG 6 race, 6 days of life) were equally divided in two groups: treatment group (which received a commercially available feed and 250 ml of homeopathic mixture of *Calcarea carbonica* 15 CH, *Symphytum officinalis* 4 XH and *Equisetum arvensis* 4 XH diluted in a 20% hydroalcoholic solution) and the control group (which only received the commercially available feed) for the whole growing cycle (150 days). During the cycle we performed clinical evaluations of motor and reactive skills to highlight possible differences between the two groups.

Between the 125th and the 130th day of life, a total of 20 turkeys (13 belonging to the homeopathic and 7 to the control group) were taken randomly and evaluated at the veterinary CT Center of Rome where three separate measurements were carried out at the level of femur and humerus diaphysis and middle third of the sternum.

## STATISTICAL ANALYSIS

Data were analyzed using GraphPad Prism 6 software (GraphPad Software, Inc., La Jolla, CA, USA). All data are presented as the means  $\pm$  standard error of the mean and

**Figure 1.** Graphical representation of (A) bone density increase of femur diaphysis expressed in UH (Hounsfield units), before and after 150 days treatment with the homeopathic mixture, \*\*\*\* $P < 0.0001$ ; (B) bone density increase of humerus diaphysis before and after 150 days treatment with the homeopathic mixture, \*\*\*\* $P < 0.0001$ ; (C) bone density increase of middle third of the sternum before and after 150 days treatment with the homeopathic mixture, \*\*\*\* $P < 0.0001$ .



were first checked for normality using the D’Agostino-Pearson normality test. Differences in bone density of femur and humerus diaphysis and middle third of the sternum at the end of treatment versus baseline between the 2 groups were analyzed using a one-way analysis of variance (ANOVA) followed by a Tukey’s multiple comparisons test.

**RESULTS**

In Figure 1, the overall significant improvement of bone density of femur and humerus diaphysis and middle third of the sternum, before and at the end of the 150 days evaluation, is shown (\*\* $P < 0.01$ ).

As to the clinical aspect, treated subjects were more reactive, tonic, and vital than controls. Moreover, an overall decreased number of animals discarded during the cycle was also observed in the treated group, 2/20 (10%), with respect to the control group, 6/20 (32%).

**CONCLUSIONS**

Farmed turkeys usually have low bone tissue mineralization, and this deficiency creates an overall weakness of the animal with a negative impact on the health. The administration of substances with a bone tissue tropism can induce an improvement of health quality and disease resistance of these animals. The CT measurements show that bone density increased in a significant manner in turkeys treated with the homeopathic mixture with respect to the controls. The present study, which has to be considered preliminary, is one of the first scientific evidence of the effectiveness of homeopathic substances diluted and potentized beyond Avogadro constant. It may be the first support for the thousands of clinical evidences, which are the daily heritage of the veterinary homeopaths around the world. However, considering the

randomized system of choice and the homogeneity of the results obtained, it is highly likely that a future work, based on these indications, can confirm both scientific aspect of this research and the potential of homeopathic medicine in intensive livestock, with important consequences on human health.

### LIST OF ABBREVIATIONS

XH = 1/10 dilution rate according to Hahnemann method

CH = 1/100 dilution rate according to Hahnemann method

CT = Computerized Tomography

### AUTHORS' CONTRIBUTIONS

SC, PB, MG and LDA conceived the study, participated in its design and coordination and carried out the animal food administration and veterinary visits. ADC helped to draft the manuscript. All authors read and approved the final manuscript.

### REFERENCES

1. Herscu P: Homeopathic Treatment of Children: Pediatric Constitutional Types. Berkeley, California: North Atlantic Books; 1991.
2. Sakakura CE, Neto RS, Bellucci M, Wenzel A, Scaf G, Marcantonio E, Jr.: Influence of homeopathic treatment with comfrey on bone density around titanium implants: a digital subtraction radiography study in rats. *Clinical oral implants research* 2008, 19:624-628.
3. Bessa Pereira C, Gomes PS, Costa-Rodrigues J, Almeida Palmas R, Vieira L, Ferraz MP, Lopes MA, Fernandes MH: Equisetum arvense hydro-methanolic extracts in bone tissue regeneration: in vitro osteoblastic modulation and antibacterial activity. *Cell Prolif* 2012, 45:386-396.
4. Frost R, MacPherson H, O'Meara S: A critical scoping review of external uses of comfrey (*Symphytum* spp.). *Complementary therapies in medicine* 2013, 21:724-745.
5. Araujo LU, Reis PG, Barbosa LC, Saude-Guimaraes DA, Grabe-Guimaraes A, Mosqueira VC, Carneiro CM, Silva-Barcellos NM: In vivo wound healing effects of *Symphytum officinale* L. leaves extract in different topical formulations. *Die Pharmazie* 2012, 67:355-360.
6. Caverio RY, Akerreta S, Calvo MI: Pharmaceutical ethnobotany in Northern Navarra (Iberian Peninsula). *J Ethnopharmacol* 2011, 133:138-146.
7. Wood M: Herbal Treatment for the Muscular and Skeletal System. Independence, Minnesota: Sunnyside Herb Farm; 2007.
8. Mathie RT, Baitson ES, Hansen L, Elliott MF, Hoare J: Homeopathic prescribing for chronic conditions in feline and canine veterinary practice. *Homeopathy: the journal of the Faculty of Homeopathy* 2010, 99:243-248.
9. Dewey WA: *Essentials of Homeopathic Therapeutics*. Pomeroy, WA; 1993.
10. Qin M, Zhang Z, Maki K, Naito M, Morimoto A, and, Kimura M: The effect of calcium supplement given with a mixture of calcium carbonate and calcium citrate on the mandibular alveolar bone of pubertal rats. *J Bone Miner Metab* 1998, 16.
11. Hodiament G: Trattato di farmacologia omeopatica. In *IV Piante medicinali in omeopatia*. Edited by Ipsa E. Palermo; 1988: 255-259
12. Rees PA: Dictionary of Zoo Biology and Animal Management. Wiley; 2013.